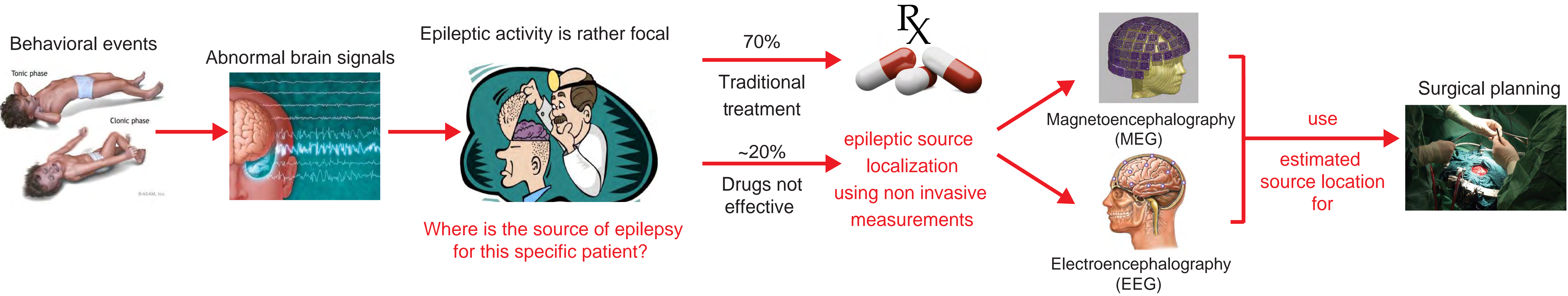
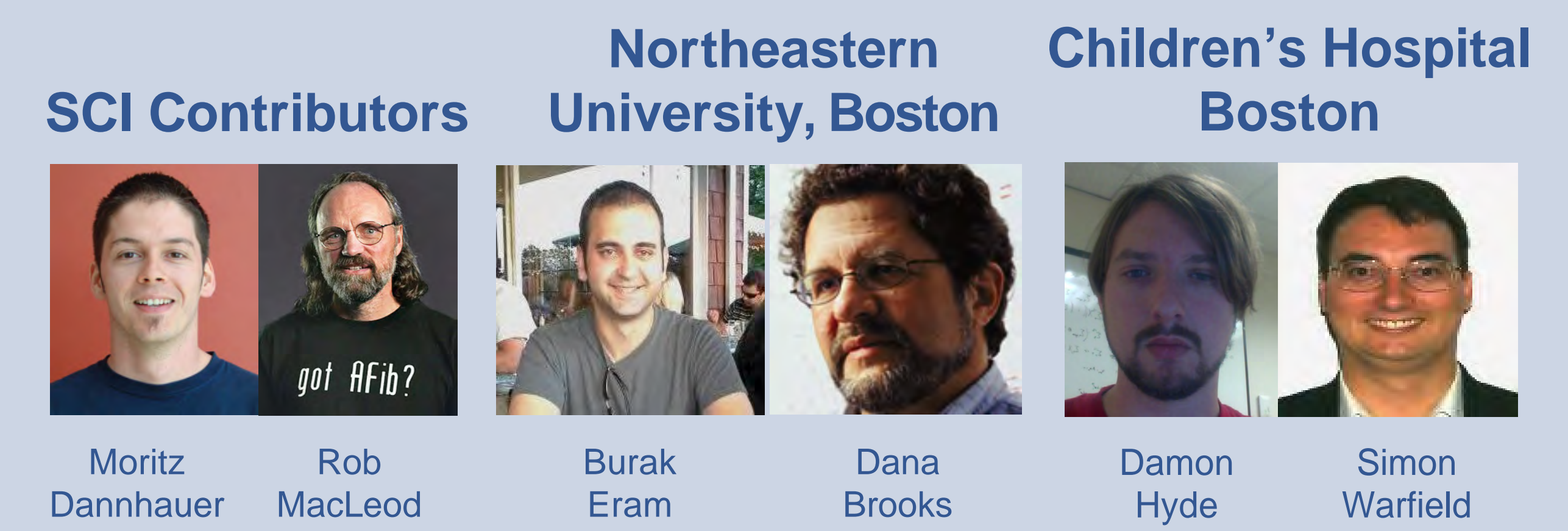

Epilepsy - Identifying Epileptical Sources in the Human Brain



Case Study

- 11 year old boy
- medically intractable epilepsy
- tumor anterior to motor area

Source Localization Pipeline

